

An Old Entity with a Chinese Perspective

Speaker: YF Shea

Supervisor: LW Chu

Inter-hospital Geriatric Meeting

26-8-2011

History

- 79/M.
- Lived alone.
- Wife lived in USA.
- Chronic smoker for over 30 years.
- Social drinker.
- Walk unaided.
- Activities of daily living independent.
- Followed up in geriatric clinic in QMH.

History

- Type II diabetes mellitus (HbA1C 7.5%).
- Hypertension.
- Hyperlipidemia.
- Bilateral carotid stenosis (50% on magnetic resonance angiography).
- Pulmonary tuberculosis more than 10 years ago (completed six months of therapy).
- Presbycusis for 10 years.
- Psoriasis.

History

Medications:

- Clopidogrel 75 mg daily po.
- Simvastatin 20 mg nocte po.
- Perindopril 6 mg daily po
- Gliclazide 160 mg BD po.
- Sitagliptin 50 mg daily po.
- Emulsifying ointment as soap daily LA.
- Liquid paraffin: white soft paraffin 1:1 LA BD prn.
- Betnovate ointment 0.1% LA BD.

Noted the following blood results

	Aug, 2010	Normal range
Alkaline phosphatase (ALP; U/L)	245	42-110
Total calcium (mmol/L)	2.68	2.24-2.63
Adjusted calcium (mmol/L)	2.66	2.24-2.63
Phosphate (mmol/L)	1.04	0.88-1.45
Albumin (g/L)	43	39-50
Globulin (g/L)	32	24-37
Creatinine (umol/L)	126	67-109

- WBC $7.40 \times 10^9/L$.
- Platelet $202 \times 10^9/L$.
- Hb 12.8 g/dL.

History

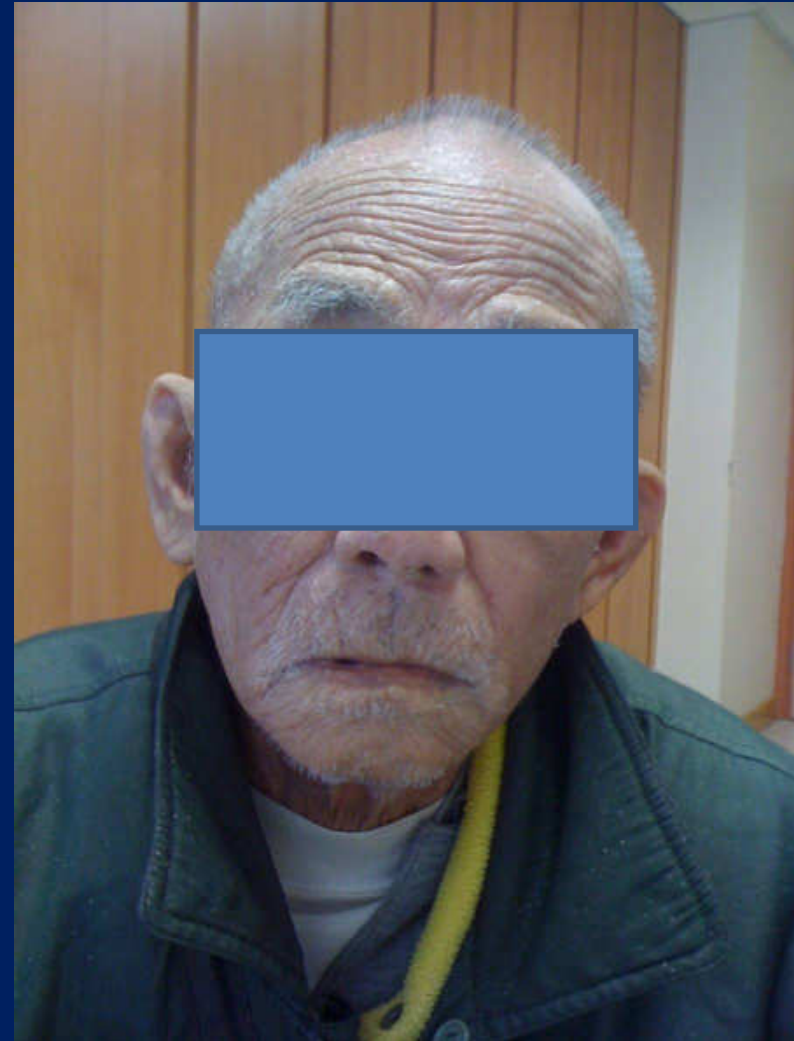
- No bone pain.
- No constipation. Bowel opening once per day.
- No muscle weakness.
- No dyspepsia, no anorexia, no vomiting.
- No polyuria or polydipsia.
- No passage of urinary stones.

History

- No hemoptysis. No fever.
- No per-rectal bleeding.
- No intake of over the counter medications.
- No family history of endocrine disease.

Physical examination

- BP 143/79, pulse 70 bpm.
- SaO₂ 99% room air.
- Body height 1.57m, BW 58 kg, BMI 23.5 kg/m².
- Bilateral hearing impairment.
- No skull bone enlargement.
- No long bone deformity.
- Normal respiratory, cardiovascular or abdominal examinations.



Physical examination

- Neurological examination: hyporeflexia over the bilateral ankle jerks, vibration sense +ve right ankle.
- Weber test central and Rinnie test normal (air conduction better than bone conduction).
- Per-rectal exam: 3 fingers breath prostate and median groove preserved.

Lab investigations

	Dec, 2009	Aug, 2010	Sept 2010	Normal range
Alkaline phosphatase (ALP; U/L)	252	245	298	42-110
Heat stable ALP (U/L)	-	-	45	-
Fraction	-	-	0.15	-
Total calcium (mmol/L)	2.72	2.68	2.56	2.24-2.63
Adjusted calcium (mmol/L)	2.66	2.66	2.56	2.24-2.63
Phosphate (mmol/L)	1.01	1.04	1.09	0.88-1.45
Gama-glutamyl transferase (GGT; U/L)	65	-	-	11-62
Creatinine (umol/L)	133	126	118	67-109
Parathyroid hormone (PTH pmol/L)	2.0	-	3.9	1.1-7.3

Usage of ALP fraction

ALP fraction

- Liver ALP is more stable than bone ALP at 56 degree Celsius.
- So, we heat the specimen in a water bath for 10 minutes before we measure ALP activity.
- <20% of the serum ALP activity remains, the enzyme present is largely of bone origin. If >35% remains, it indicates probable liver origin.

Personal communication with Dr. Matthew Yeung of Laboratory of Clinical Biochemistry,
QMH

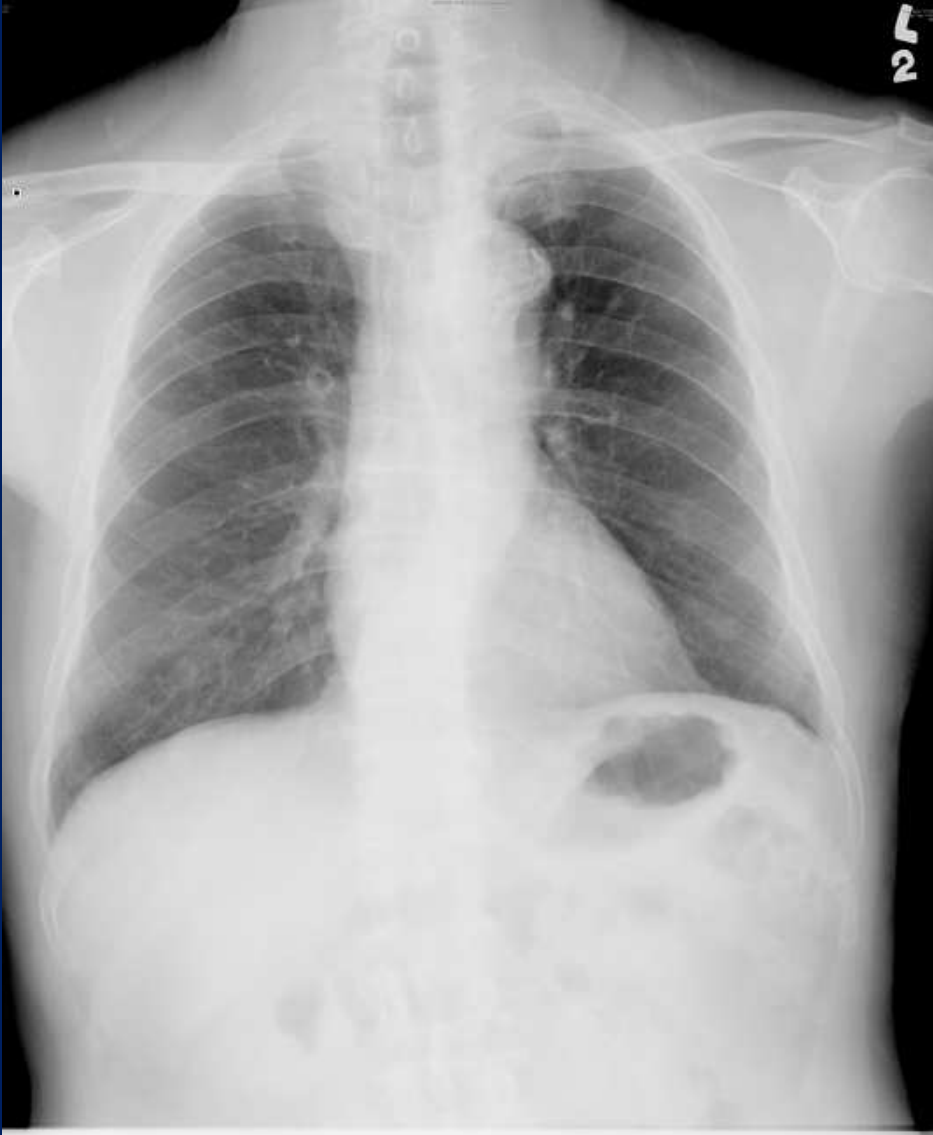ALP fraction

- In reality, there is some degree of overlap between heat inactivation of liver and bone fractions in both liver and bone diseases.
- Also, this manual test is subjected to imprecision due to difficulties in standardizing the procedure.
- The diagnostic accuracy is roughly 93%

Other investigations results

- Alpha-fetoprotein – normal.
- Prostate specific antigen – normal.
- Carcinoembryonic antigen (CEA) **7.8 ng/ml** (N <5 ng/ml).
- Hemoglobin 11.8 g/dL.
- Stool occult blood negative for twice.
- Ultrasound abdomen in Jan, 2010: normal.

Chest X-Ray



CXR unremarkable

So far...

- 78/M patient.
- Chronic smoker.
- With asymptomatic hypercalcemia.
- Elevated ALP – suggestive of bone origin.
- With low normal level of PTH.
- Slightly elevated CEA.
- Differential diagnoses include...

Differential Diagnosis

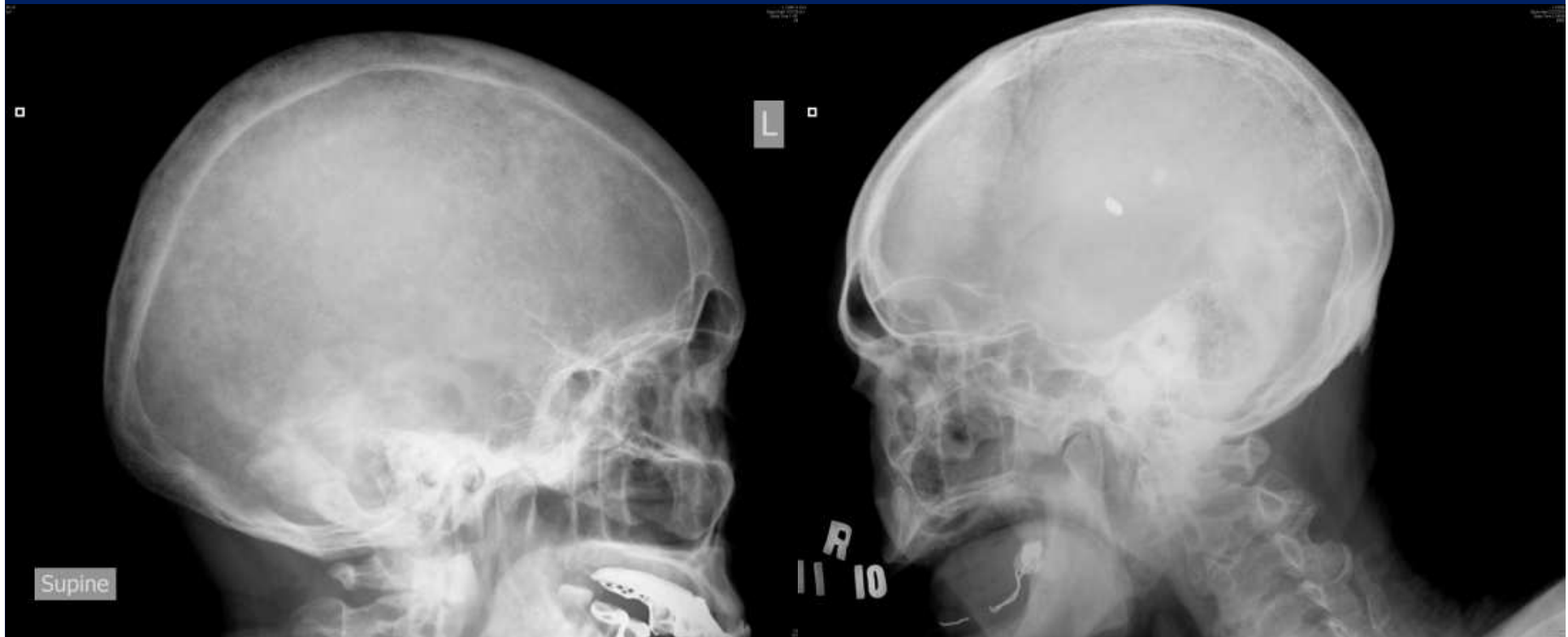- **Internal malignancy e.g. carcinoma of lung with bone metastases.**
- **Primary hyperparathyroidism.**
- **Paget's disease.**

**We ordered skeletal survey and
gallium bone scan.**

Skull X-ray

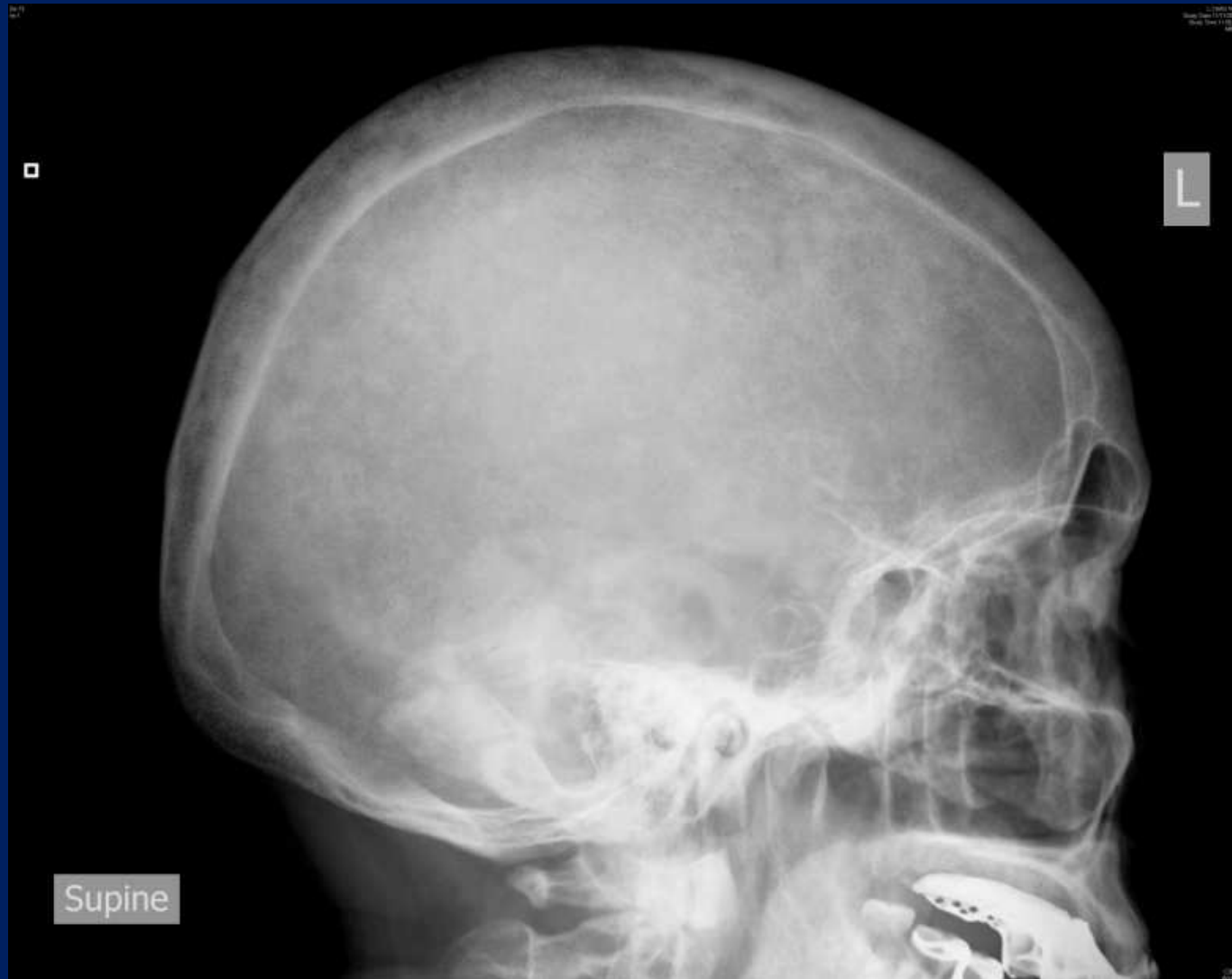Current patient

Another patient

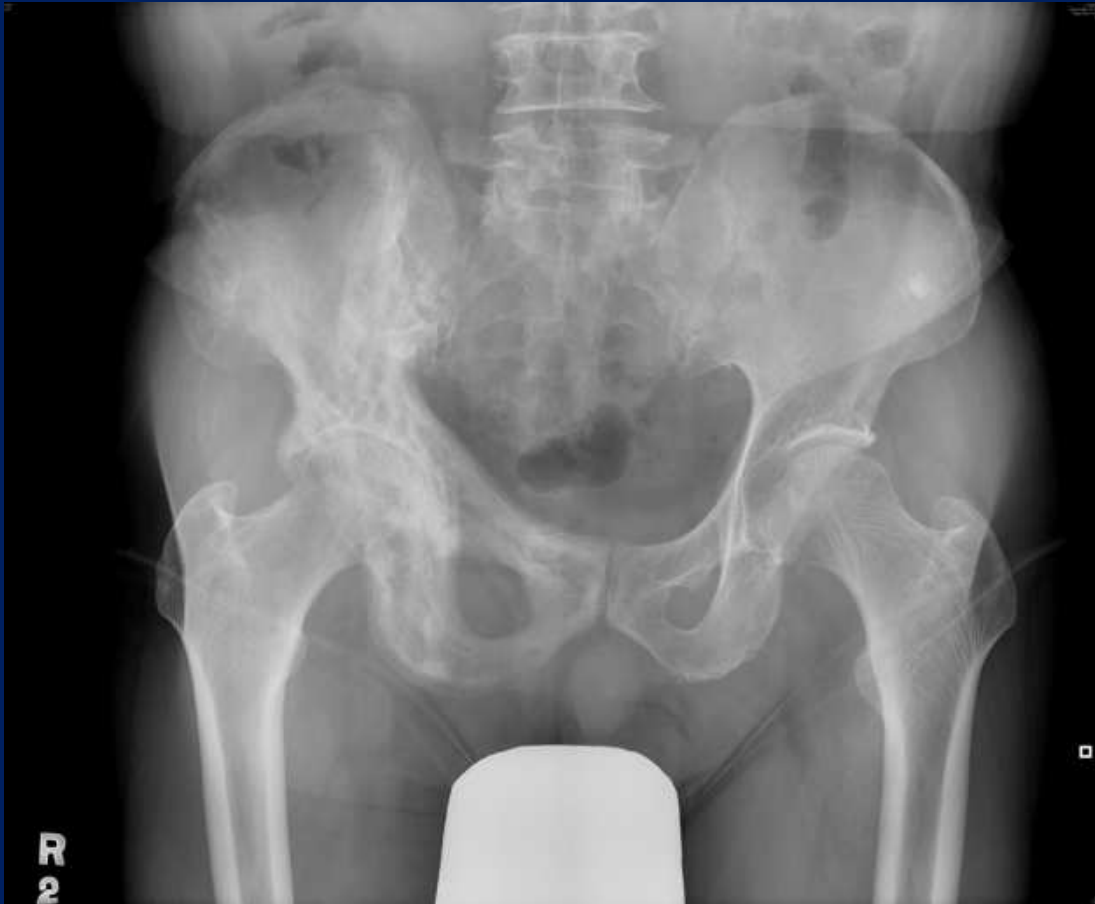

Cotton wool appearances of the skull X-ray

Skull X-ray

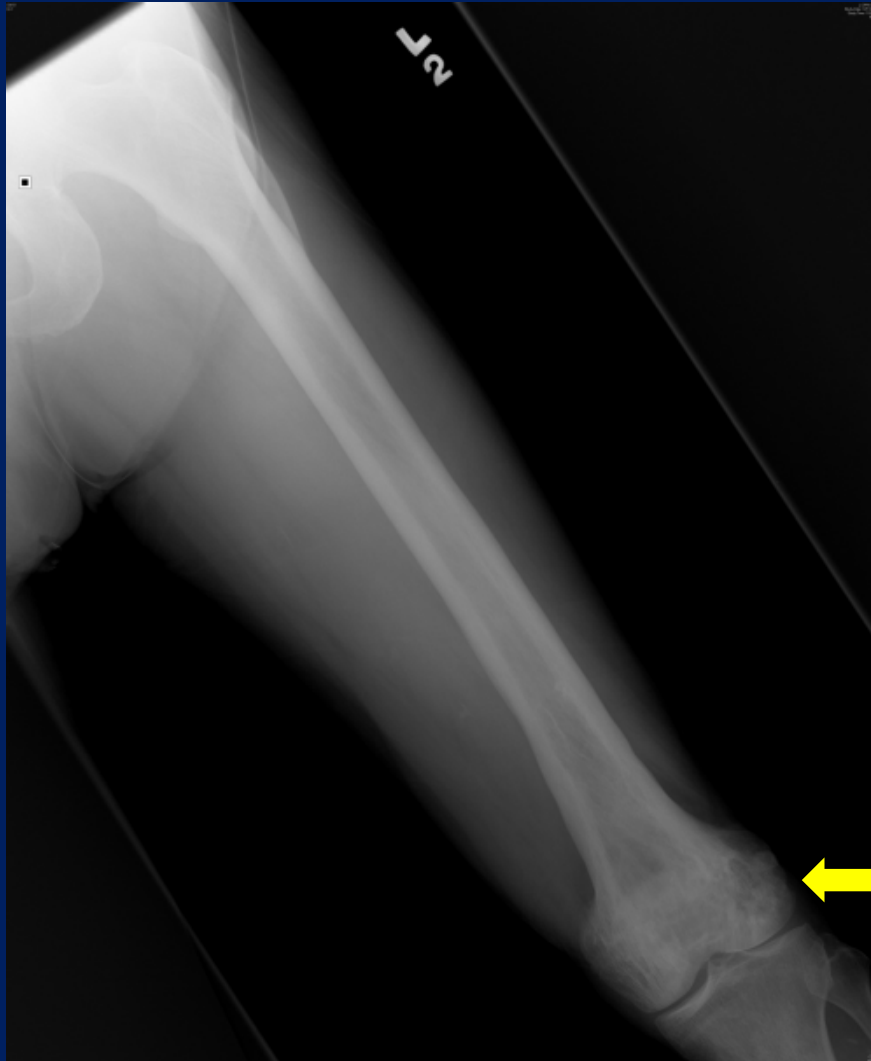

Pelvis XR



Right hemi-pelvis showed osteosclerosis alternating with areas of osteolysis and bone expansion.

Left femur X-ray



Lt distal femur also showed the typical radiological features of osteosclerosis alternating with areas of osteolysis and bone expansion.

Radiologically, there were evidence of Paget's disease.

Hypercalcemia in a patient who could walk independently

? Bone metastases

? Primary hyperparathyroidism

**Let's have a review on the
Paget's disease before we go
back to our patient**

Epidemiology of Paget's disease

- **Western countries.**

- 1-2% of white adults > 55 yrs old.
- UK: 5-8% by 8th decade.

- **Asian countries.**

- Incidence < 2% in Asia.
- Prevalence in Japan 2.8 per million.
- Chinese: Just 10 isolated case reports from PubMed.

Reference:

1. Pathogenesis and management of Paget's disease of bone. Lancet . Vol 372 July 12, 2008.
2. Paget's disease of the bone in a Chinese woman. Australasian Radiology (2005), 505-507.
3. Prevalence and clinical features of Paget's disease of bone in Japan; J Bone Miner Metab 2006 24:186-190.

Classification

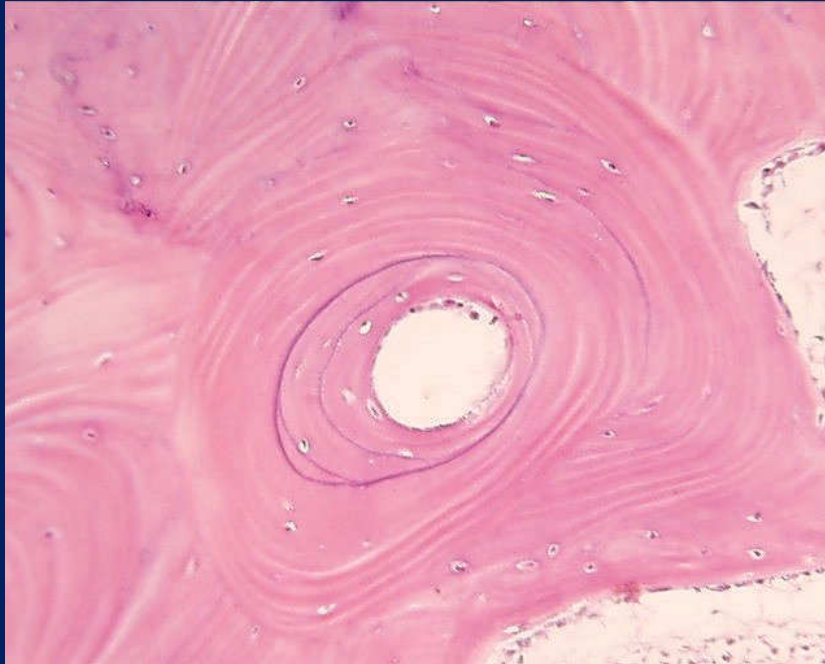
- **Mono-ostotic** versus **poly-ostotic**.
- Axial skeleton is preferentially affected.
 - Pelvis, femur, spine, skull, tibia

Pathophysiology

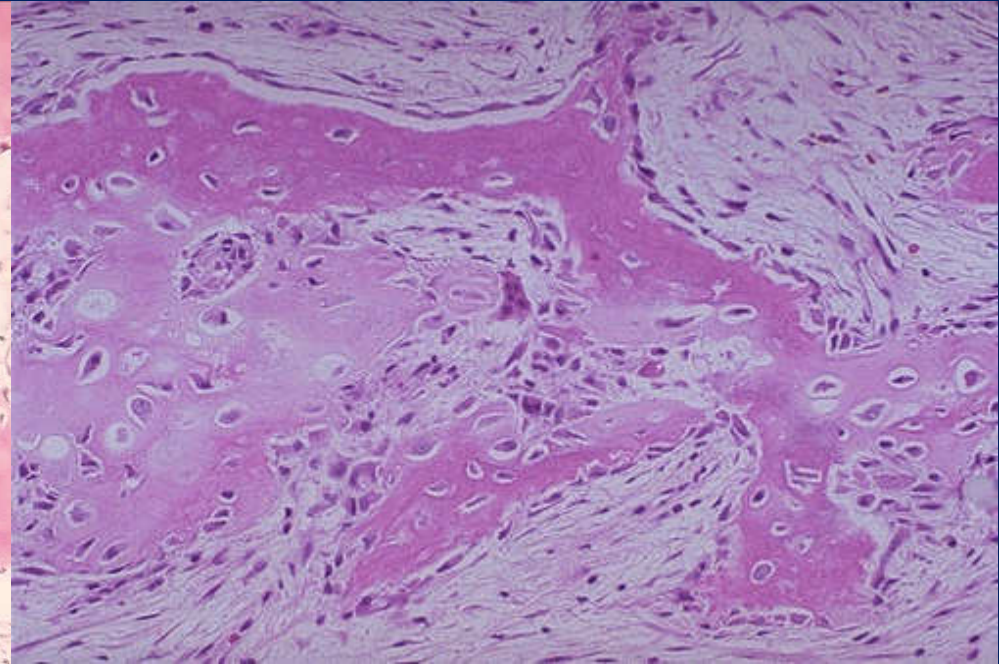
- Uncontrolled osteoclastic erosion.
- Excessive osteoblastic activity.
- **Dis-organized bone formation.**
 - Mixture of lamellar and woven bone.
 - Increased vascularity.
- Increased risk of deformities and fractures.

Reference: Pathogenesis and management of Paget's disease of bone. Lancet . Vol 372 July 12, 2008.

Normal Bone

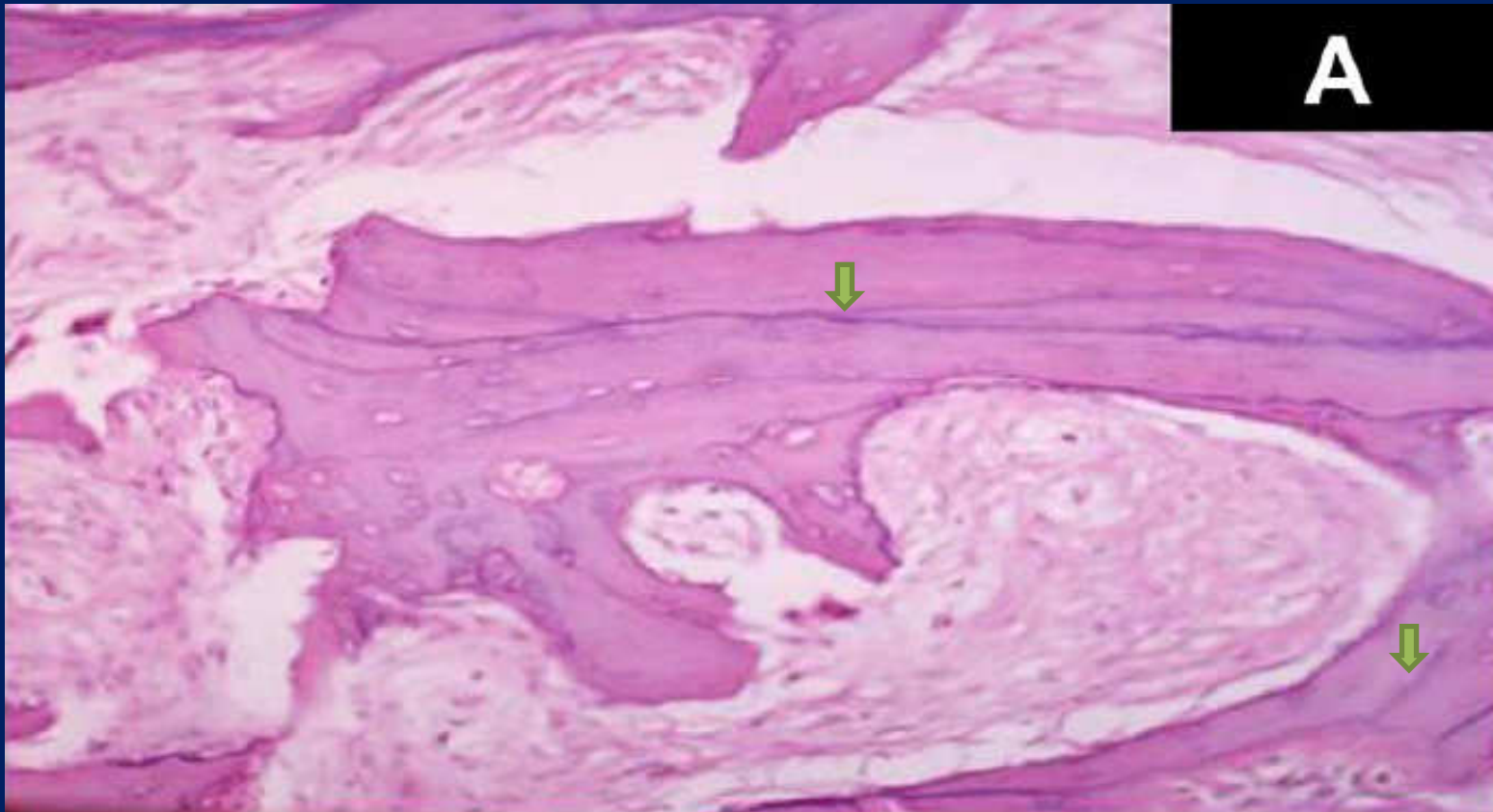


Lamellar bone



Woven bone

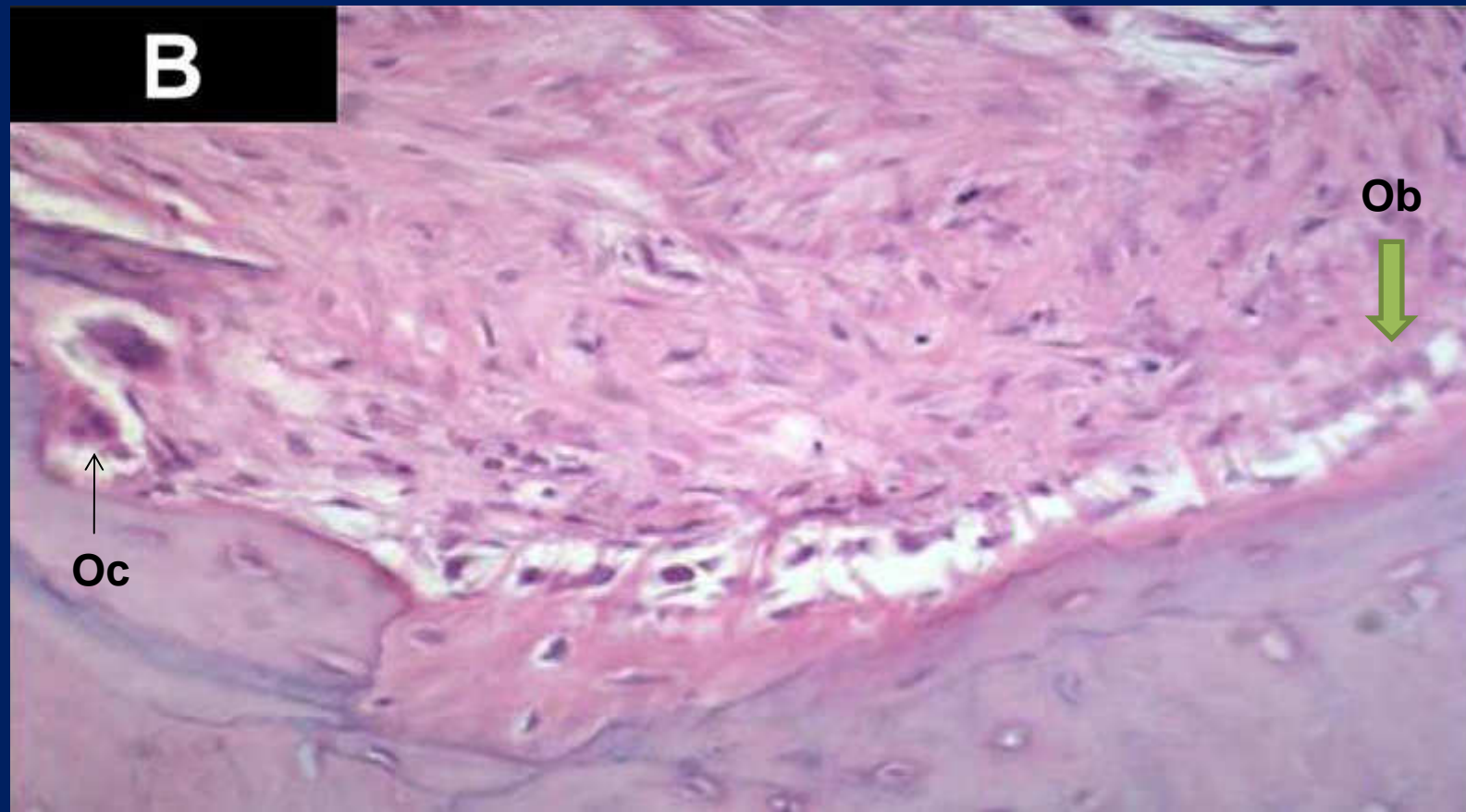
Histopathology



↑ Mosaic lines – haphazardly oriented units of lamellar bone

Reference: Wang WC, Cheng YS, Chen CH, Lin YJ, Chen YK, Lin LM, et al; Paget's disease of bone in a Chinese patient: a case report and review of the literature [Review]. Oral Surg Oral Med Oral Pathol Oral Radiol Endod. 2005 Jun;99(6):727-33.

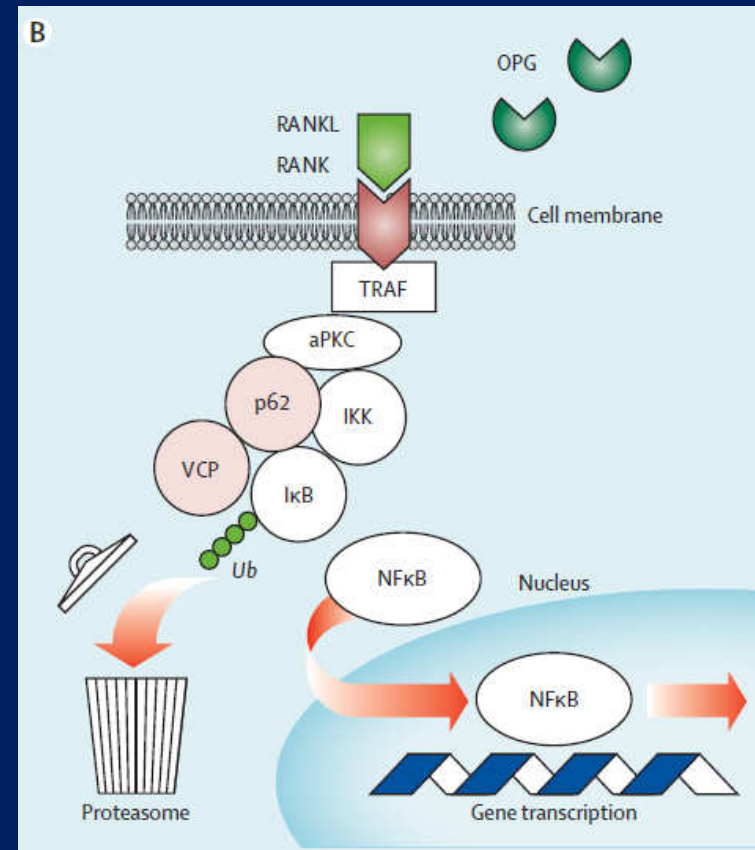
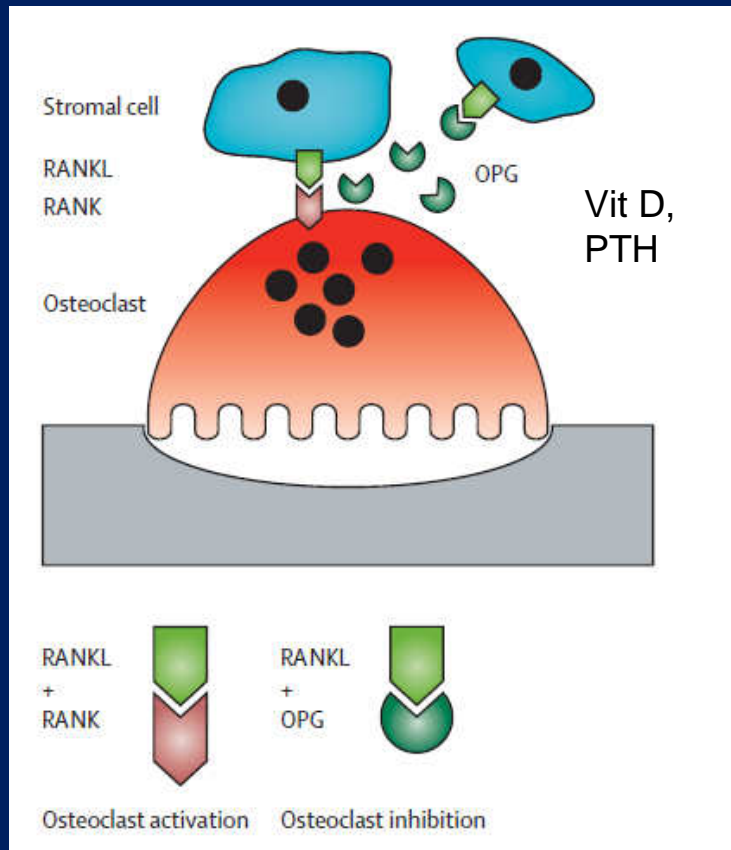
Histopathology



Oc – osteoclasts; Ob - osteoblasts

Reference: Wang WC, Cheng YS, Chen CH, Lin YJ, Chen YK, Lin LM, et al; Paget's disease of bone in a Chinese patient: a case report and review of the literature [Review]. Oral Surg Oral Med Oral Pathol Oral Radiol Endod. 2005 Jun;99(6):727-33.

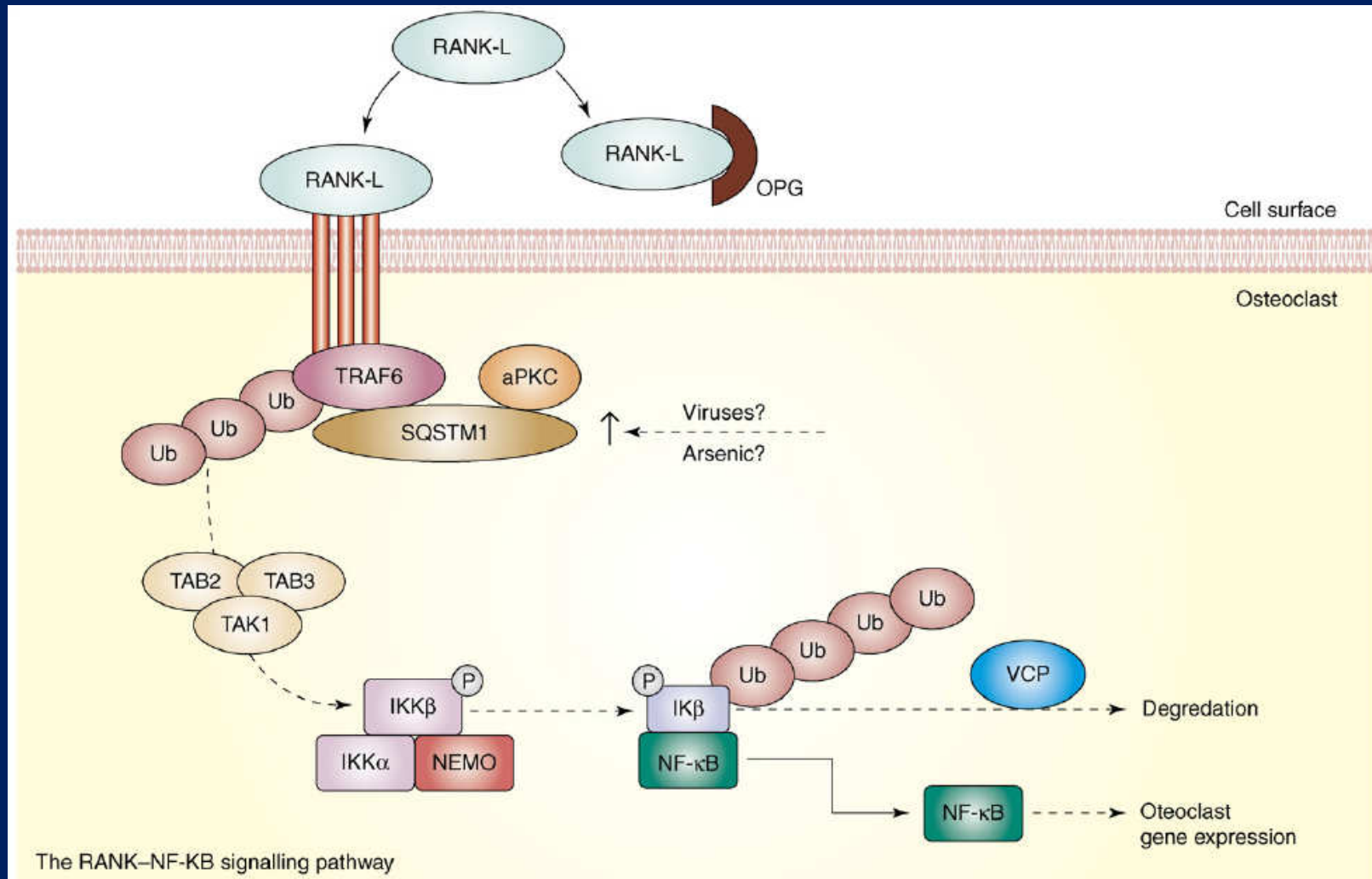
Pathophysiology



Local mechanical stress might affect the distribution of bone lesion

Reference: Pathogenesis and management of Paget's disease of bone. *Lancet* . Vol 372 July 12, 2008.

Pathophysiology



Reference: Cundy T, Bolland M, et al; Paget's disease of bone; Trends in Endocrinology and metabolism 2008 (19);7; 246-253

Pathophysiology

- Role of paramyxovirus.
 - **Nuclear** or less commonly **cytoplasmic inclusions** similar to nucleocapsids.
- Measles virus, RSV, canine distemper virus.

Reference: Roodman GD, et al; Insights into the pathogenesis of Paget's disease; Ann N.Y. Acad. Sci. 1192 (2010) 176-180

Clinical features

- Mean age at diagnosis: ~ 74 years old.
- 15-33% - +ve family history.
- 7-10 times higher in 1st degree relatives.
- Familial.
 - Autosomal dominant trait with high penetrance.
 - Earlier presentation.
 - More aggressive.
 - 4 genes e.g. Sequestosome 1 (SQSTM1).

Reference:

1. Pathogenesis and management of Paget's disease of bone. *Lancet* . Vol 372 July 12, 2008.
2. Cundy T, Bolland M, et al; Paget's disease of bone; *Cell* (2008) 246-253

Clinical features

- Bone pain.
 - Mechanical or rest or night pain.
- External bone deformity.
- Increased skin temperature over the affected bone.

Clinical features: Complications

- Deafness (61%).
- Pathological fractures.
- 2nd osteoarthritis.
- Spinal stenosis.
- Nerve compression.
- Hydrocephalus.
- Paraplegia.
- Cardiac failure.
- Osteosarcoma (0.1-0.2%).

Reference:

1. Pathogenesis and management of Paget's disease of bone. Lancet . Vol 372 July 12, 2008.
2. Paget Disease of Bone; J Clin Rheumatol 2008; 14: 299-305.

Hypercalcemia in Paget's disease

- Active polyostotic disease and immobilization & dehydration.
- Primary hyperparathyroidism.
- Malignancy..

Reference:

1.Paget's Disease of Bone; N Engl J Med 2006; 355:593-600.

2.Pathogenesis and management of Paget's disease of bone. Lancet . Vol 372 July 12, 2008.

Case Reports of Paget's disease in Chinese Patients

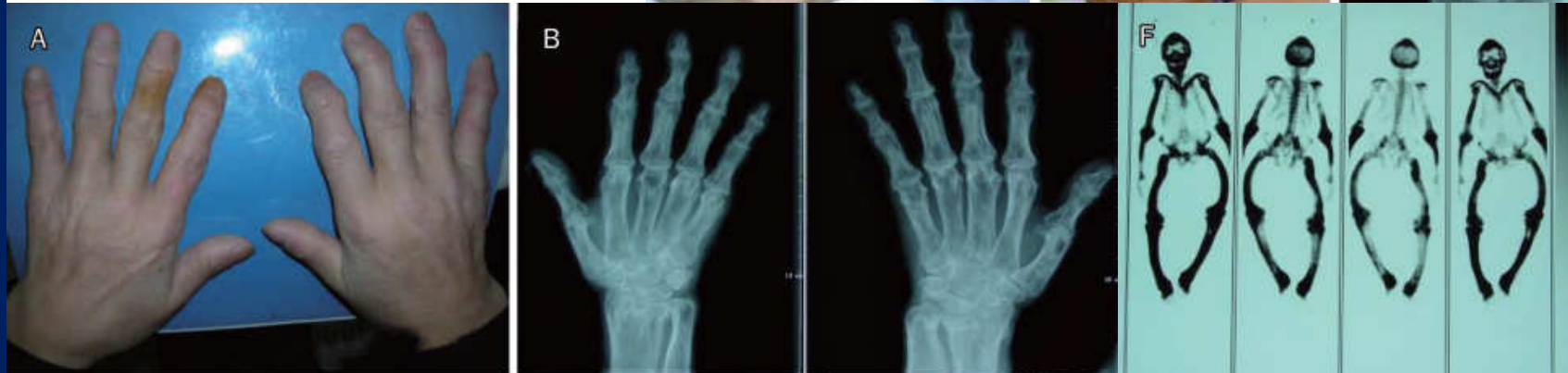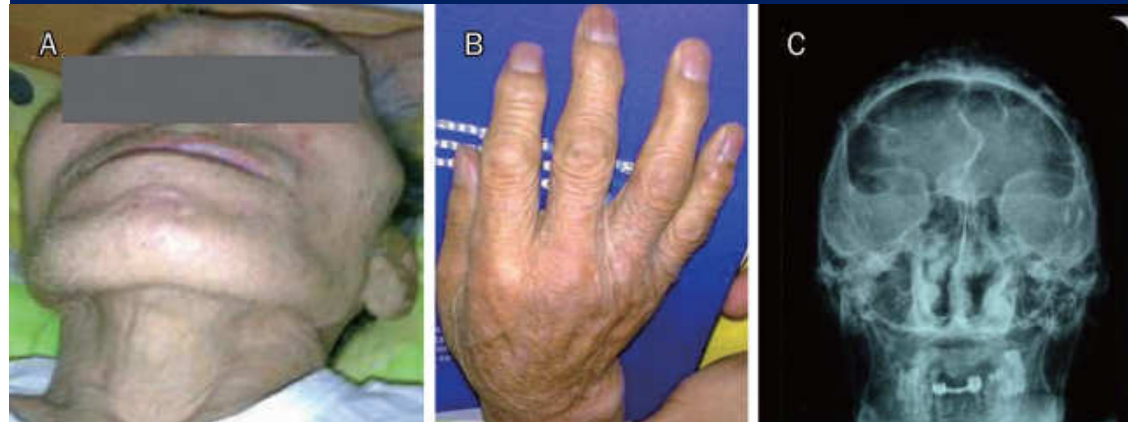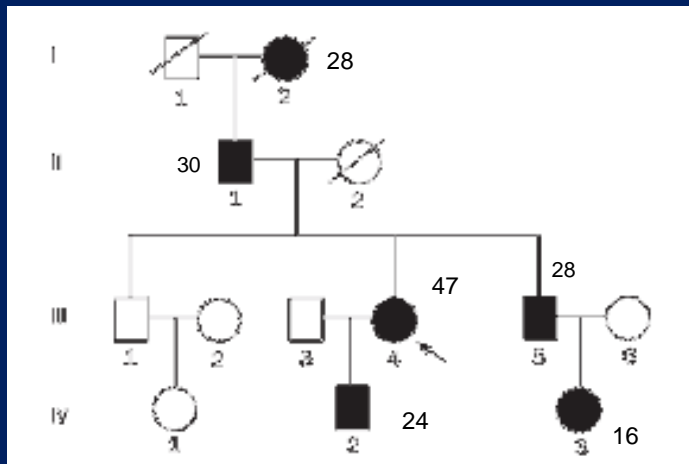
Case	Authors	Country	Age/ sex	Sites	Symptoms and signs	Treatment	Follow-up
1	Khoo, 1995	Malaysia	57/M	3 rd lumbar vertebral body	No	No	Stabilized, 10 mths
2	Sirikulchayanonta, 1991	Thailand	44/F	Skull, clavicle, lumbar spine, sacrum	Bone pain	Calcitonin	-
3	Yip, 1996	Hong Kong	91/M	Skull, jaw and tibia	Enlarged skull, broad forehead, wide jaw, bowed tibia and deafness	No	-
4	Hsu, 1998	Singapore	78/F	Skull & pelvis	No	No	-
5	Hsu, 1998	Singapore	61/M	Pelvis	Bone pain	No	-
6	Hsu, 1998	Singapore	53/F	Tibia	Bowel tibia	No	-
7	Hsu, 1998	Singapore	80/M	Pelvis, hip, vertebral body, sacrum	Bone pain, pelvic bone expansion, deafness	Yes	-
8	Wang, 1999	Taiwan	66/F	Tibia	Bone pain	Sodium cloronate	Stabilized, 16 mths
9	Wang, 2005	Taiwan	54/M	Skull, jaw, ribs, spine	Enlarged skull, broad forehead, wide jaw, blurred vision	Surgery	Pathological # of ribs, 6 mths
10	Hung, 2008	Taiwan	59/F	Facial bone (no other details)	No	No	Noted Ca pancreas

Clinical Features in Chinese Patients

	Paget's disease in Chinese Patients	Paget's disease in Western Countries
Sites of Involvement	Spine and sacrum (40%), skull (40%), pelvis (30%), tibia (30%), jaw (20%), clavicle (10%), rib (10%), femur (10%)	Pelvis and sacrum (58.3%), spine (36.6%), femur (31.6%), tibia (20%), skull (19%), jaw (17%), rib (4.3%), clavicle (3.8%)
Mean Age (M:F)	64.3 years old (1:1)	>40 years old (1:1 to 3:1)
Monoostotic	40%	17-31%
Asympomatic cases	30%	67%-95%
Symptoms and signs in symptomatic patient	Bone pain, deformity, neurological symptoms	Bone pain, deformity, neurological symptoms
Treatment	Calcitonin, sodium cloronate, surgery	Bisphosphonates, calcitonin, surgery
Familial cases reported	Yes (78dup27 of the TNFRSF11A gene)	Yes, 14% of the patients
Malignant transformation	No	Yes

Reference: Table Modified from Paget's disease of the bone in a Chinese Patient: A case report and review of the literature; Pathol Oral Radiol Endod 2005; 99: 727-33

Familial Paget's disease in a Chinese Family



Reference: Early onset Paget's disease of bone caused by a novel mutation (78dup27) of the TNFRSF11A gene in a Chinese family; *Acta Pharmacologica Sinica* (2009) 30: 1204-1210

Familial Paget's disease in a Chinese Family

- Autosomal dominant.
- Relatively young.
- Affect the axial, skull bones and small hand joints.
 - Involvement of mandible and maxilla.
- TNFRSF11A gene encodes RANK.

Reference: Early onset Paget's disease of bone caused by a novel mutation (78dup27) of the TNFRSF11A gene in a Chinese family; Acta Pharmacologica Sinica (2009) 30: 1204-1210

Laboratory Investigations of Paget's disease

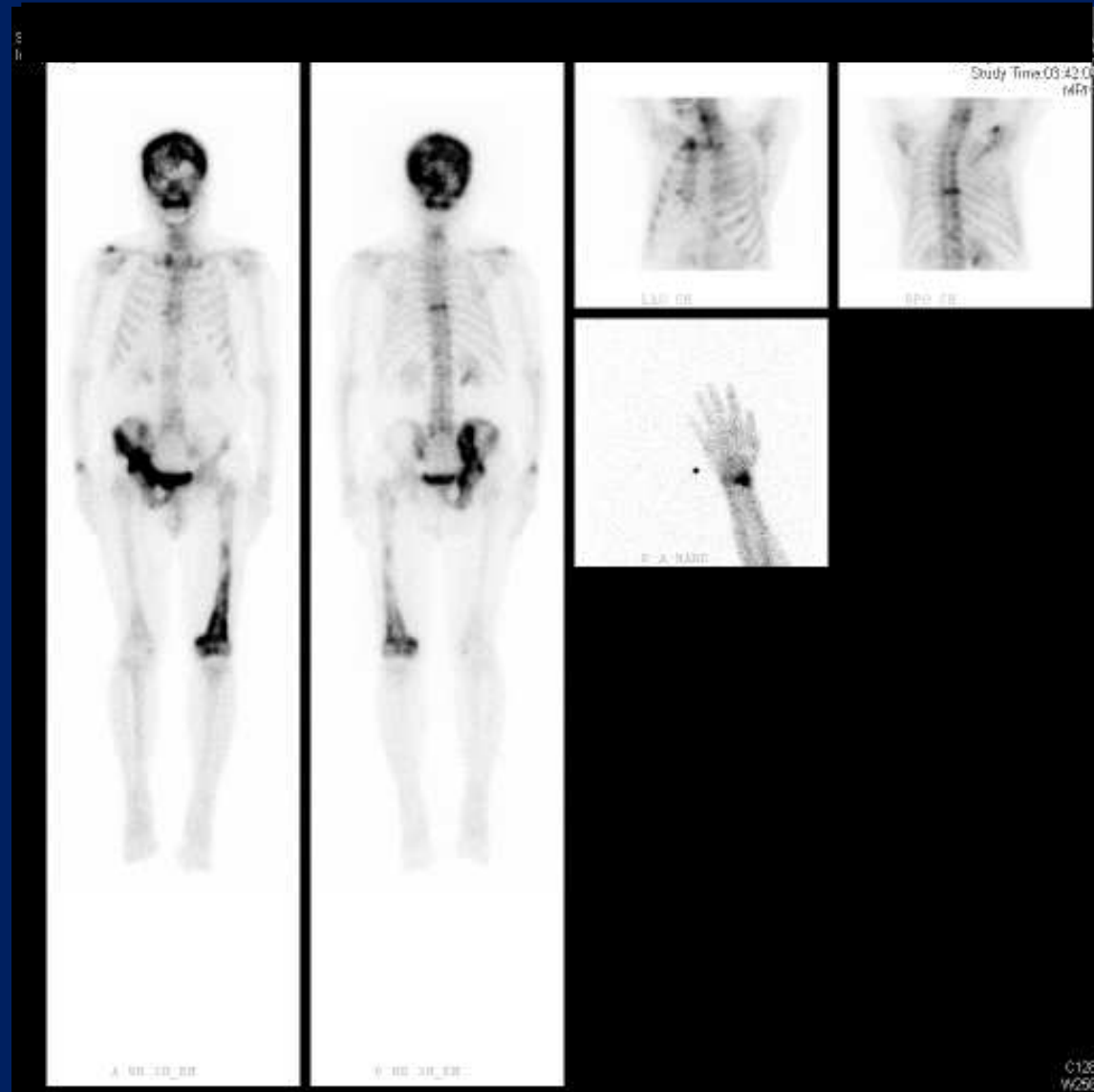
Laboratory investigations

- **Raised alkaline phosphatase (ALP).**
 - In 95% of the untreated patients.
- Could be normal in mono-ostotic disease or in those metabolically inactive disease.

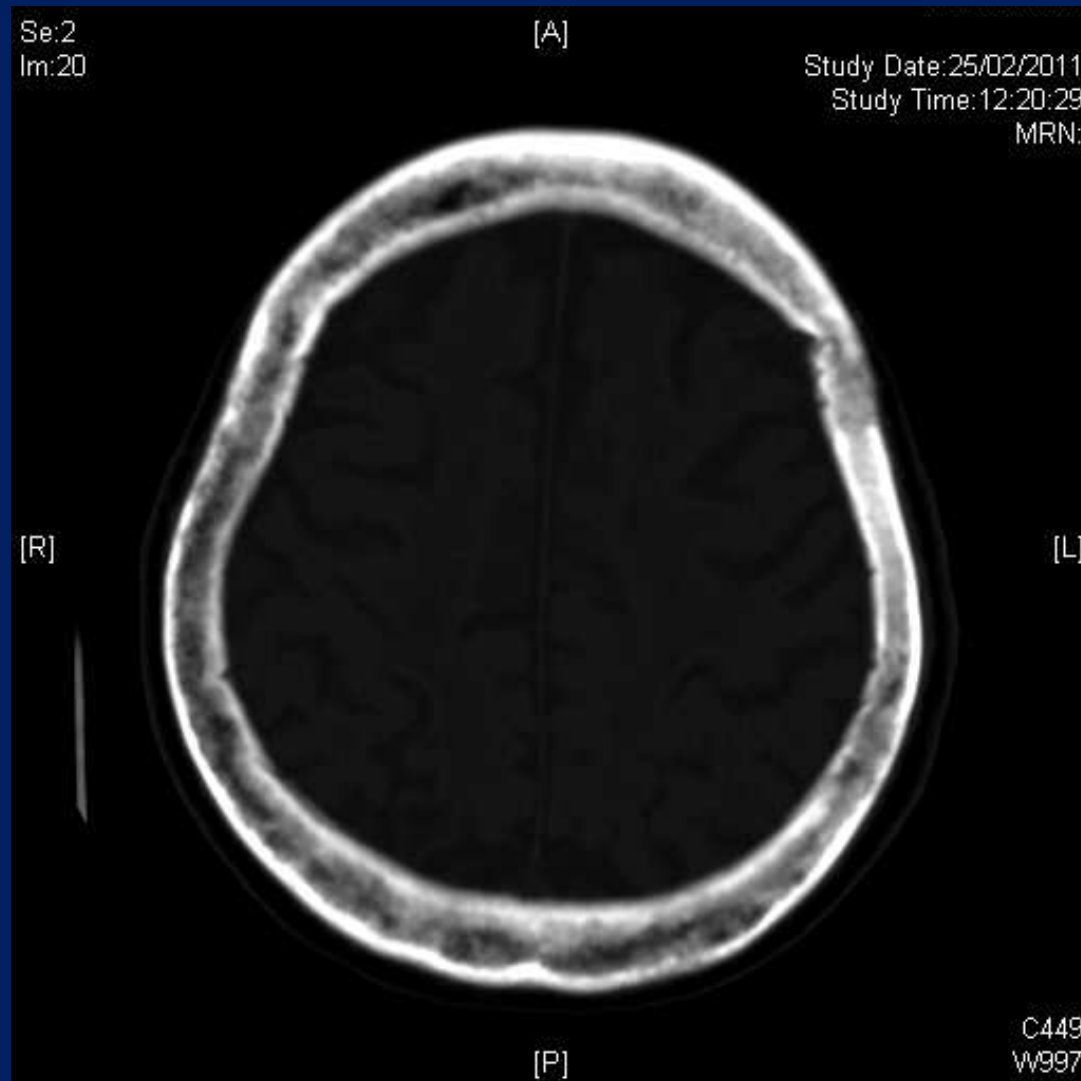
Further investigations

- **Bone scan.**
 - Define the extent of the disease.
- **Bone biopsy.**
 - In ethnic group with rare occurrence.
 - E.g. In Japan.

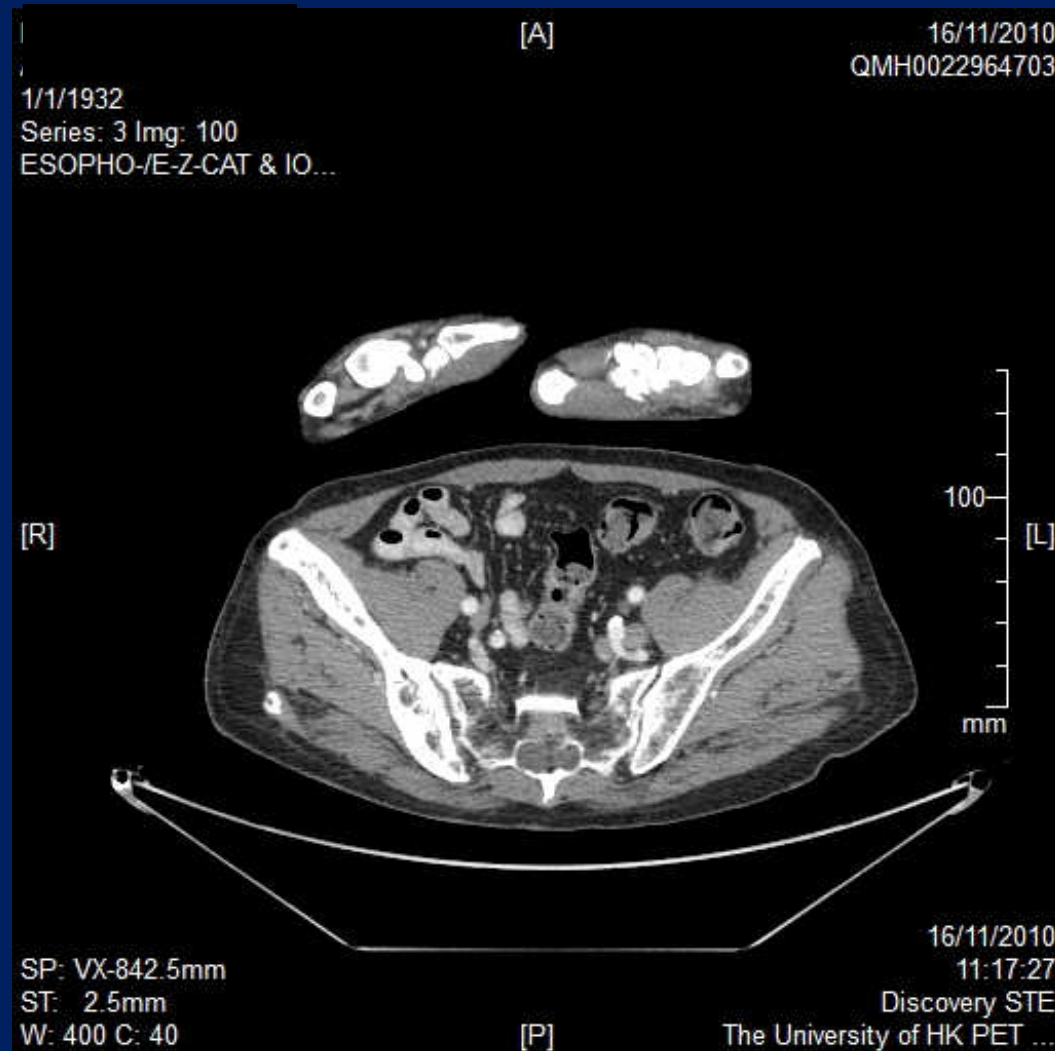
Bone scan of our patient



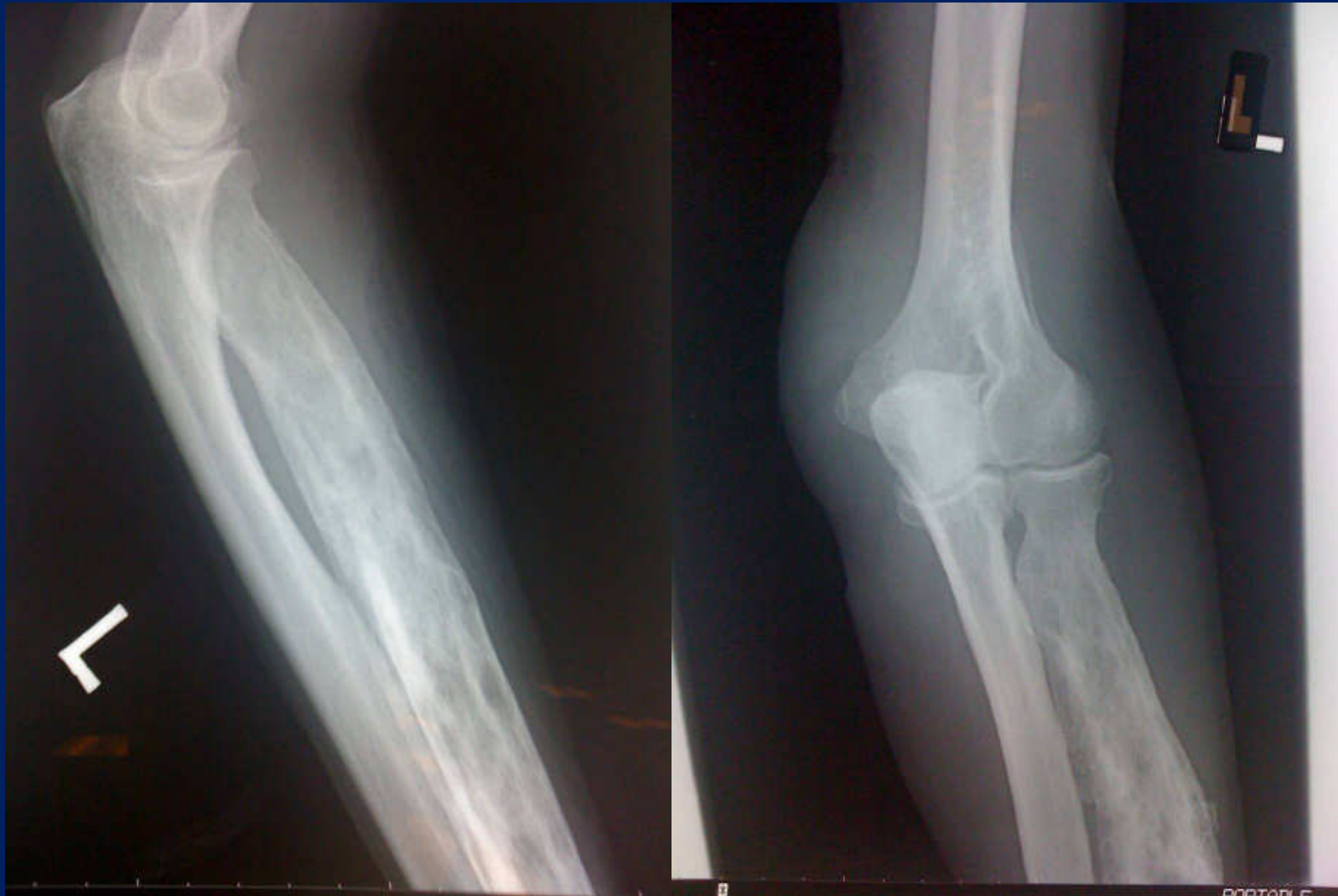CT brain with bone window



CT pelvis



Another patient



Progress of our patient

- The patient was prescribed with **pamidronate**.
- Because of involvement of disease in weight bearing area.
- ALP and calcium level subsequently normalized.

Medical treatment - Indications

- **Symptoms** resulting from the active bone lesion.
- **Prophylaxis** in asymptomatic patients.
- **Elective surgery** for Pagetic sites e.g. joint replacement.
 - ?Reduced blood loss.
- **Hypercalcemia** resulting from immobilization.

Reference:

1. Paget's Disease of Bone; N Engl J Med 2006; 355:593-600.

2. Pathogenesis and management of Paget's disease of bone. Lancet . Vol 372 July 12, 2008.

Medical treatment

- **Anti-resorptive therapy.**
 - Reduce the number and activity of osteoclasts.
- There are **no studies** to establish whether bisphosphonates are effective at preventing complications of Paget's disease.

Reference:

1. Cundy T, Bolland M, et al; Paget's disease of bone; Trends in Endocrinology and metabolism 2008 (19);7; 246-253.
2. Pathogenesis and management of Paget's disease of bone. Lancet . Vol 372 July 12, 2008.

Medical treatment

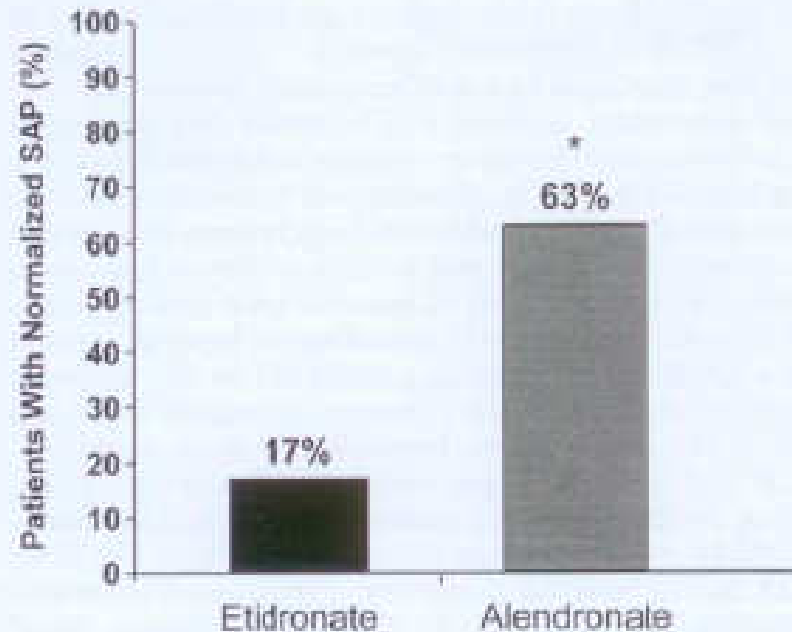
Drug	Recommended dosages and administration	Side effects
Pamidronate	30-60 mg IV over 4 hrs for 3 days	Transient flu-like illness (10-25%), hypocalcemia, short lived iritis, bone pain, osteonecrosis of the jaw
Zoledronic acid	5mg IV single infusion	Transient flu-like illness (10-25%), hypocalcemia, osteonecrosis of the jaw
Risedronate	30mg/day for 2 months	Dyspepsia, esophagitis, osteonecrosis of the jaw, iritis
Aldendronate	40 mg/day for 6 months	Dyspepsia, esophagitis, osteonecrosis of the jaw, iritis

Reference:

1.Paget's Disease of Bone; N Engl J Med 2006; 355:593-600.

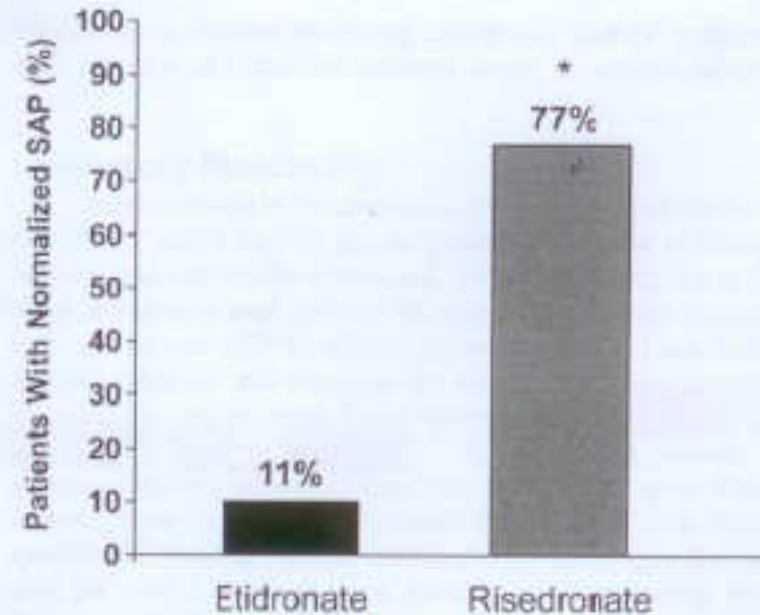
2.Pathogenesis and management of Paget's disease of bone. Lancet . Vol 372 July 12, 2008.

Efficacy of Treatment



* $P < 0.001$

FIGURE 1. Percentage of patients with normalization of serum ALP after 6 months of treatment with alendronate 40 mg/d (n = 41) or etidronate 400 mg/d (n = 47).³²

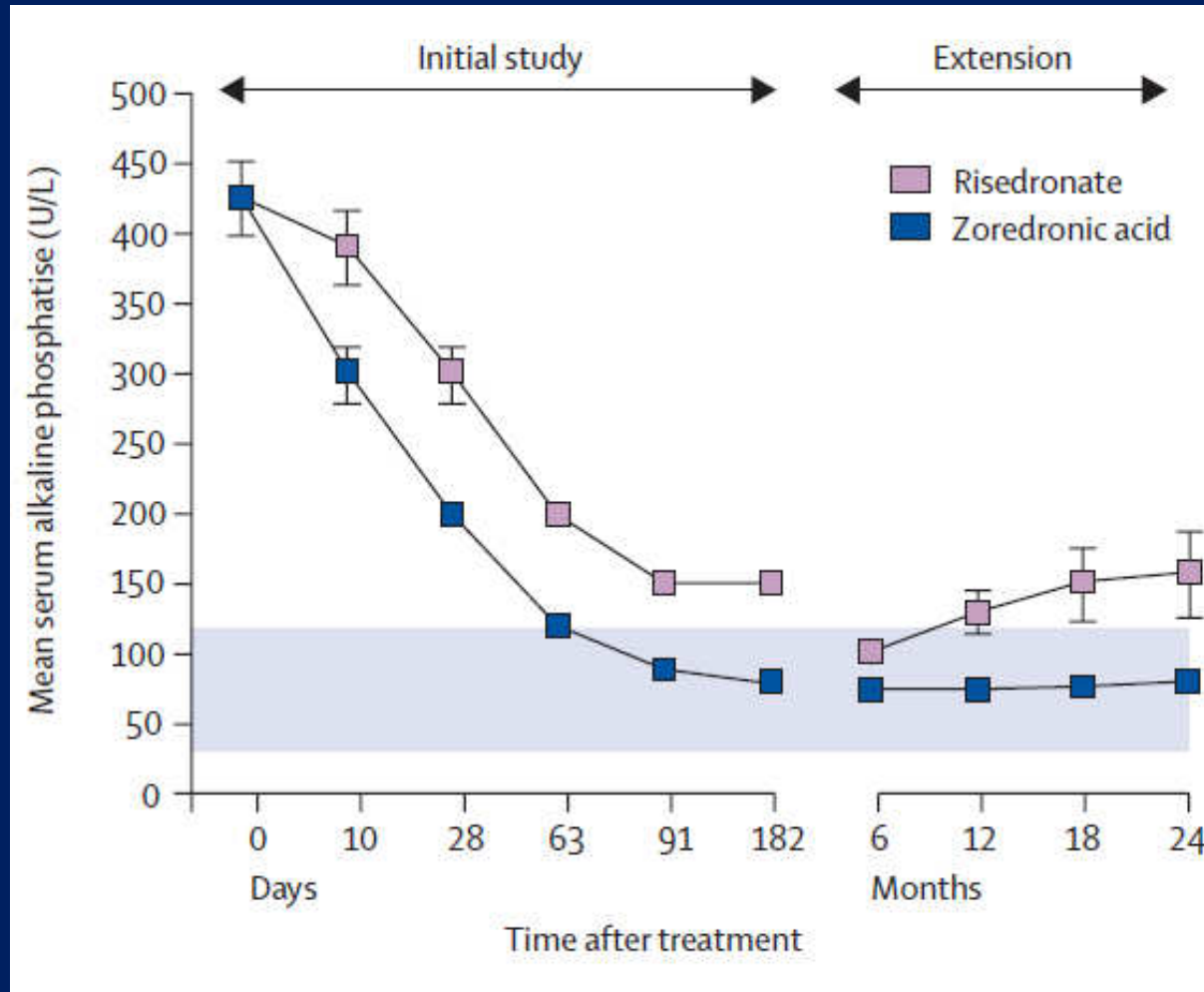


* $P < 0.001$

FIGURE 2. Percentage of patients with normalization of serum ALP at month 6 after treatment with risedronate 30 mg/d for 2 months (n = 56) or etidronate 400 mg/d for 6 months (n = 57).^{30,43}

Reference: Paget Disease of Bone Therapeutic options; J Clin Rheumatol 2008; 14: 299-305.

Medical treatment



Reference:

1. Paget's Disease of Bone; N Engl J Med 2006; 355:593-600.

2. Pathogenesis and management of Paget's disease of bone. Lancet . Vol 372 July 12, 2008.

Supportive treatments

- Pain control: panadol, NSAIDs.
- Physiotherapy.
- Hydrotherapy.
- Transcutaneous electrical nerve stimulation.
- Assistive devices – walking sticks, shoe raises, heel lifts, crutches.

Reference:

- 1.Pathogenesis and management of Paget's disease of bone. Lancet . Vol 372 July 12, 2008.
- 2.Paget Disease of Bone; J Clin Rheumatol 2008; 14: 299-305.

Surgical treatments

- Joint replacement for osteoarthritis.
- Fracture fixation.
- Osteotomy to correct bone deformity.
- Spinal stenosis.
- Painful pseudofractures.
- Osteosarcoma

Monitoring of disease activity

- **ALP (e.g. ↑ 15%) and development of clinical symptoms.**
 - Monitor ALP initially every 3 mths for the first 6 months and then every 6 mths thereafter.
- Indicated for **re-treatment.**
- No evidence of lower ALP are accompanied by beneficial effects on the disease associated complications.

Reference:

1. Paget's Disease of Bone; N Engl J Med 2006; 355:593-600.
2. Pathogenesis and management of Paget's disease of bone. Lancet . Vol 372 July 12, 2008.
3. Paget Disease of Bone Therapeutic options; J Clin Rheumatol 2008; 14: 299-305.

**We also attempted to rule out
internal malignancy with
positron emission tomography.**

Fluorine-18-FDG PET in Paget's Disease of Bone

- 18 patients with Established Paget's Disease.
 - 11 men, 7 women.
 - Mean age 71 years old.
- Mean ALP levels (normal < 126 U/L) – 275 U/L.
- 13 patients had received pamidronate at a mean of 19 months (1-48 mths) before the scan.

Fluorine-18-FDG PET in Paget's Disease of Bone

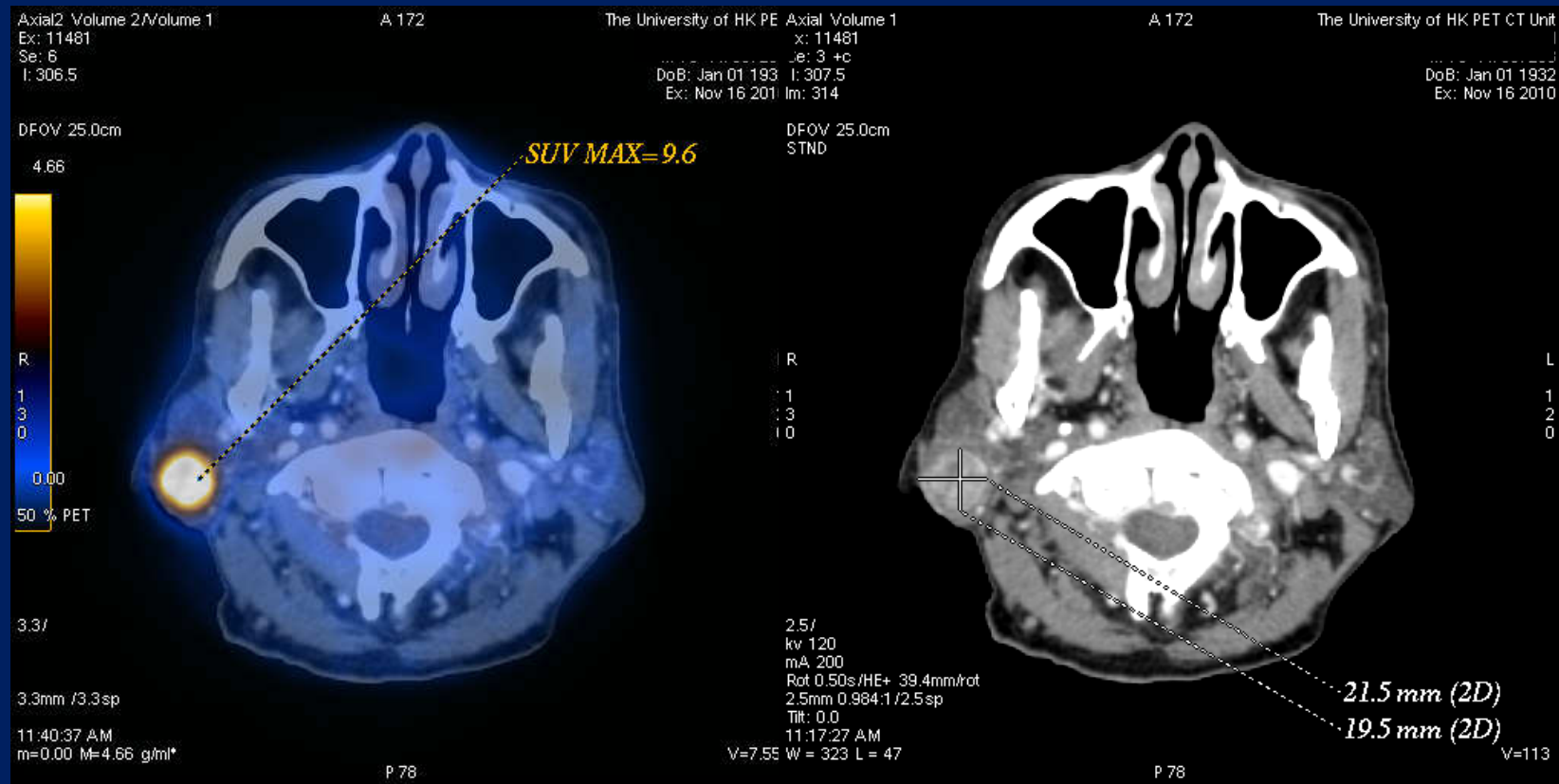
- 66 bones abnormal on bone scan versus 16 on PET scans.
- 6 of 18 patients showed abnormal PET scan uptake.
 - 3 with low uptake i.e. less than the liver.
 - 3 with marked uptake: cortical distribution.
 - Mean serum ALP 520U/L (all > 280 U/L) versus for patients with normal PET scan 153U/L.
- For those with previous bisphosphonate therapy.
 - 5 out of 6 patients with abnormal PET scans.
 - 8 out of 12 patients with normal PET scan.

Reference: Fluorine-18-FDG PET in Paget's Disease of Bone; J Nucl Med 1997; 38: 1495-1497

Fluorine-18-FDG PET in Paget's Disease of Bone

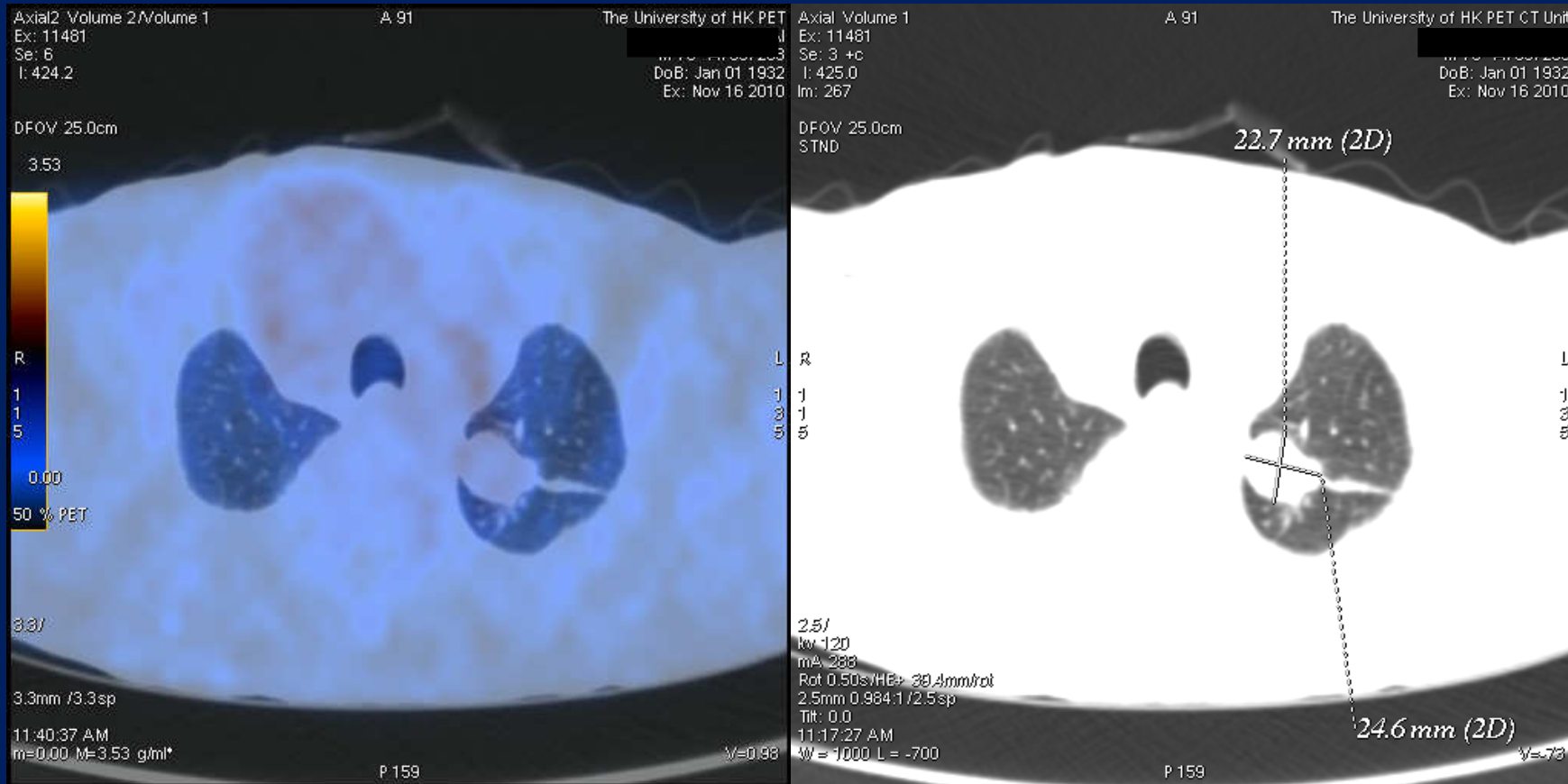
- **Conclusion:**
 - Paget's disease of bone is not associated with abnormal FDG PET scan uptake.
 - Potential to use it to differentiate between benign Paget's disease and associated sarcoma.
 - Negative study requires no further investigation.

PET-CT of our patient



Fine needle aspiration of the right parotid gland showed features of Warthin tumor and decided for conservative management.

PET-CT of our patient



Eumetabolic lesion in the left apical region with surrounding fibrosis which can be due to previous chest infection

Progress of our patient

- We shall monitor Lt upper lung shadow with interval computed tomography of the thorax.
- We have booked the parathyroid 99m-Tc-Sestamibi scan but the patient defaulted the follow-up because of recent admission.

Elevated CEA due to smoking

- Smoking increased the expression of mRNA and protein expression of CEA in lung tissues.
- Related to recruitment of neutrophils into the lower respiratory tracts.

Reference: Hookah smoking and cancer: carcinoembryonic antigen (CEA) levels in exclusive/ever hookah smokers.
Harm Reduct J. 2008 May 24;5:19.

Overall Diagnosis

- Polyostotic Paget's disease in a Chinese patient.
- Still need to watch out for primary hyperparathyroidism.

Learning Points

- Learn the approach to hypercalcemia.
- Review Paget's disease in Chinese.

Thank you for your attention